OPEN ACCESS Freely available online

ISSN 3139-2946

Journal of Innovative Dental Sciences

Review Article

Oral Submucous Fibrosis and Oral Cancer: Pathogenesis, Malignant Transformation, and Current Diagnostic Approaches

Harshit Kumar[1*], Himanshu Lakherwal[2], Abhishek Parmar[3], Dinesh Kumar Negi[4]

[1,2,3,4] *Dentistry, Himachal institute of Dental sciences, Paonta Sahib, IND*

ABSTRACT

Oral submucous fibrosis (OSMF) is a chronic, progressive, and potentially malignant disorder of the oral cavity, strongly associated with areca nut chewing and the use of areca nut-containing products. It is characterized by excessive collagen deposition, juxtaepithelial inflammation, mucosal stiffness, and progressive restriction of mouth opening. OSMF is of considerable clinical significance because of its potential for malignant transformation into oral squamous cell carcinoma (OSCC). The pathogenesis of this transformation is complex and involves areca nut-associated carcinogenic effects, oxidative stress, chronic inflammation, tissue hypoxia, altered extracellular matrix metabolism, genetic and epigenetic changes, and dysregulation of cellular signaling pathways. This review discusses the biological mechanisms underlying OSMF-associated carcinogenesis, summarizes the available evidence on malignant transformation, and evaluates current diagnostic approaches for identifying early malignant changes. Clinical examination, histopathological assessment, and biopsy remain central to diagnosis, while adjunctive methods, including vital staining, optical techniques, and molecular biomarkers, are being investigated to improve early detection. Although systematic reviews indicate a measurable risk of malignant transformation, reported estimates vary because of differences in study populations, follow-up periods, and methodological quality. Long-term clinical surveillance, cessation of areca nut and tobacco use, and prompt investigation of suspicious mucosal changes are essential components of patient management. Further welldesigned longitudinal studies are needed to validate molecular biomarkers and establish reliable strategies for predicting malignant transformation. A better understanding of OSMF associated carcinogenesis may support earlier diagnosis, risk stratification, and improved clinical outcomes.

Keywords: Oral submucous fibrosis; Oral squamous cell carcinoma; Malignant transformation; Areca nut; Carcinogenesis; Oral potentially malignant disorders; Molecular biomarkers; Early diagnosis

INTRODUCTION

Globally, oral cancer is a serious public health issue, especially in South and Southeast Asia where betel quid, tobacco, and areca nut consumption are still common [1]. Oral squamous cell carcinoma (OSCC) is responsible for the vast majority of malignant lesions that emerge in the mouth cavity [2]. Although there have been improvements in diagnostic and therapeutic techniques, the lag in diagnosis continues to lead to significant morbidity and mortality [3]. Oral potentially malignant disorders (OPMDs) are vital as they detect individuals and oral mucosal regions that are at an elevated likelihood of progressing to oral cancer [4]. Oral submucous fibrosis (OSMF) is one such disorder and is particularly prevalent in populations where areca nut consumption is common [5].

OSMF is achronic, progressive fibrotic disorder characterized by juxtaepithelial inflammation, fibroelastic changes in the lamina propria, and excessive collagen deposition within the oral submucosal tissues [6]. Clinically, patients may present with a burning sensation, intolerance to spicy foods, blanching of the oral mucosa, palpable fibrous bands, reduced tissue elasticity, and progressive restriction of mouth opening [7]. In advanced cases, fibrosis can significantly impair oral function, including mastication, speech, and maintenance of oral hygiene [8]. Areca nut exposure is considered the principal etiological factor, although individual susceptibility, nutritional factors, and other

***Correspondence to:** Harshit Kumar, Dentistry, Himachal institute of Dental sciences, Paonta Sahib, IND, E-mail: kharshit909@gmail.com

Received: October 26, 2026; **Manuscript No:** JDSS-26-3133; **Editor Assigned:** October 30, 2026; **PreQc No:** JDSS-26-3133 (PQ); **Reviewed:** November 16, 2026; **Revised:** November 17, 2026; **Accepted:** November 18, 2026; **Published:** November 21, 2026

Citation: Kumar H, Lakherwal H, Parmar A, Negi DK (2026). Oral Submucous Fibrosis and Oral Cancer: Pathogenesis, Malignant Transformation, and Current Diagnostic Approaches. J Innov Dent Sci. Vol.2 Iss.1, November (2026), pp:30-42.

Copyright: © 2026 Harshit Kumar, Himanshu Lakherwal, Abhishek Parmar, Dinesh Kumar Negi. This is an open-access article distributed under the terms of the Creative Commons Attribution License, which permits unrestricted use, distribution, and reproduction in any medium, provided the original author and source are credited.

co-exposures may influence disease development and progression [9].



Figure 1: Lateral intraoral clinical photograph showing extensive brown-black deposits and heavy calculus accumulation on the mandibular anterior teeth, with visible gingival recession. The adjacent oral mucosa is also visible; assessment of oral submucous fibro

OSMF is a chronic, progressive, fibrotic disease characterized by inflammation and excessive deposition of collagen within the oral submucosa. In oral healthcare, OSMF's malignant potential is a major issue. Based on nine long-term observational studies with 6,337 patients, Kujan et al.'s systematic review and meta-analysis revealed a pooled malignant transformation proportion of 4.2% among patients with OSMF. The authors did, however, note significant limitations in the evidence thThe fibrotic process is further exacerbated by persistent inflammation. Fibroblast activity and extracellular matrix synthesis are influenced by cytokines and growth factors released by inflammatory and injured epithelial cells. While prolonged epithelial damage may disrupt normal tissue homeostasis, TGF-β and other profibrotic mediators can maintain fibroblast activity. These processes offer a tenable link between fibrosis, long-term mucosal damage, and the formation of a microenvironment that may promote the development of cancer. Nonetheless, research on the precise role of individual inflammatory mediators in patients' malignant development is still ongoing at was available, such as a high risk of bias in many of the included studies [10] . A subsequent umbrella review reported estimates ranging from 4.2% to 6% across previous systematic reviews and meta-analyses, while highlighting considerable heterogeneity and methodological limitations [11]. These findings support the importance of clinical surveillance but also demonstrate the need for caution when interpreting individual risk estimates.

Malignant transformation in OSMF is caused by a variety of biological factors. The course of the disease has been linked to areca nut-associated carcinogenic effects, oxidative stress, chronic inflammation, tissue hypoxia, extracellular matrix remodeling, and changes in cellular proliferation and DNA repair [12]. Changes in molecular signaling pathways and the tumor microenvironment may further influence the transition from fibrosis and epithelial atrophy to dysplasia and invasive carcinoma. Nevertheless, the precise sequence of events responsible for malignant transformation remains incompletely understood [13].

Therefore, early detection of malignant alteration is a crucial clinical goal. When suspected changes call for further research, a histological assessment of a suitably chosen biopsy is necessary, but a traditional oral examination is still crucial. Additional diagnostic techniques, such as optical imaging, vital staining, and molecular biomarkers, have been studied for their potential to improve lesion assessment and early detection. However, these technologies differ in their diagnostic accuracy and clinical validation, and they should not be considered substitutes for histopathological assessment when biopsy is indicated [14,15,16].

This review aims to examine the relationship between OSMF and oral cancer, with particular emphasis on the pathogenesis of OSMF-associated carcinogenesis, the evidence concerning malignant transformation, and current diagnostic approaches. It also discusses the potential role of emerging biomarkers, the limitations of existing diagnostic methods, and the importance of risk-factor cessation and long-term clinical surveillance. This study aims to identify existing knowledge gaps and prioritize future research into the early identification and prevention of oral squamous cell carcinoma in patients with OSMF by integrating clinical and genomic evidence.



Figure 2: Clinical photograph of a patient with oral submucous fibrosis (OSMF), demonstrating reduced mouth opening (trismus), extensive brown-black staining, and heavy calculus deposits on the mandibular anterior teeth.

PATHOGENESIS OF ORAL SUBMUCOUS FIBROSIS AND ITS ROLE IN ORAL CARCINOGENESIS

Exposure to areca nuts, aberrant extracellular matrix metabolism, oxidative stress, chronic inflammation, and epithelial cell injury and epithelial–mesenchymal transition all combine intricately to cause OSMF. These mechanisms may provide a biological milieu conducive to the development of oral squamous cell carcinoma (OSCC) and contribute to increasing fibrosis [17,18]. However, the mechanisms responsible for fibrosis and those directly responsible for malignant transformation are related but not identical; the precise sequence linking them remains incompletely understood [19].

Areca Nut and Carcinogenic Mechanisms

The main etiological factor linked to OSMF is areca nut. It contains a number of physiologically active substances, including guvacoline, guvacine, arecoline, and arecaidine. Among them, arecoline's effects on cellular signaling, collagen metabolism, and oral mucosal fibroblasts have been thoroughly studied [20]. Areca nut exposure is also associated with carcinogenic effects, and the International Agency for Research on Cancer (IARC) has classified areca nut and betel quid without tobacco as carcinogenic to humans [21].

Arecoline can increase the synthesis and accumulation of extracellular matrix components as well as fibroblast proliferation. According to experimental research, it affects oxidative stress, transforming growth factor-beta (TGF-β) signaling, and fibroblast development into myofibroblast-like cells. These alterations aid in the formation of tissue stiffness and the gradual deposition of collagen [22,23,24]. Furthermore, exposure to areca nut-derived compounds may cause molecular changes and cellular damage related to carcinogenesis. However, the relative contribution of individual alkaloids to malignant transformation in humans requires further investigation [25].

Collagen Accumulation and Extracellular Matrix Dysregulation

An imbalance between extracellular matrix formation and breakdown causes the distinctive fibrosis of OSMF because fibroblasts synthesize collagen and other extracellular matrix components, fibroblasts are essential to this process [26]. In OSMF, increased collagen synthesis, enhanced collagen cross-linking, and impaired collagen degradation collectively contribute to the progressive accumulation of fibrous tissue [27].

One of the key regulators of this process is transforming growth factor-beta (TGF-β). Activation of the TGF-β/Smad signalling pathway stimulates fibroblast activation and promotes the expression of genes involved in collagen synthesis and extracellular matrix deposition [28]. Extracellular matrix remodeling is also regulated by mediators such as tissue inhibitors of metalloproteinases (TIMPs), lysyl oxidase (LOX), and connective tissue growth factor (CTGF). Increased collagen cross-linking and reduced matrix degradation render accumulated collagen more resistant to enzymatic breakdown, thereby contributing to persistent fibrosis.[29].

Although OSMF is characterized by extensive fibrosis, the relationship between extracellular matrix remodelling and malignant transformation is complex. Changes in tissue stiffness, cell–matrix interactions and stromal signalling may influence the local tumour microenvironment and epithelial cell behaviour. However, fibrosis alone does not inevitably result in malignant transformation, as additional molecular, genetic and microenvironmental factors are likely involved [30].

Oxidative Stress and Chronic Inflammation

Important proposed mechanism in OSMF pathogenesis and malignant transformation is oxidative stress. Cellular reactions to exposure to areca nuts and related tissue damage can result in reactive oxygen species (ROS). Oxidative damage to biological components, such as DNA, proteins, and lipids, can happen when ROS generation surpasses the ability of antioxidant defense systems. Changes in cellular signaling linked to carcinogenesis and genomic instability may be caused by persistent oxidative stress [31].

The fibrotic process in oral submucous fibrosis (OSMF) is further aggravated by persistent inflammation. Cytokines and growth factors released by inflammatory cells and injured epithelial cells influence fibroblast activation and extracellular matrix synthesis. Prolonged epithelial damage may disrupt normal tissue homeostasis, while transforming growth factor-beta (TGF-β) and other profibrotic mediators contribute to the sustained activation of fibroblasts and excessive collagen deposition. These interconnected processes provide a possible link between chronic inflammation, progressive fibrosis, persistent mucosal injury, and the development of a microenvironment that may favour malignant transformation. However, the precise contribution of individual inflammatory mediators to malignant transformation in patients with OSMF remains incompletely understood and requires further investigation [32].

Tissue Hypoxia and Hypoxia-Inducible Factors

In afflicted tissues, progressive fibrosis can change the local microvascular environment and decrease oxygen availability. Tissue hypoxia is a phenomenon that has been suggested as a possible connection between OSMF and malignant transformation. Hypoxia may affect angiogenesis, metabolism, cell survival, and the expression of genes linked to the development of tumors. An oxygen-sensitive transcriptional regulator called hypoxia-inducible factor-1 alpha (HIF-1α) regulates the expression of several genes involved in cellular adaptation to decreased oxygen supply. Changes in HIF-1α expression have been seen in OSMF tissues, indicating a potential link between hypoxia, the development of fibrosis, and malignant transformation. In this regard, HIF-1α and HIF-2α were the focus of a 2024 systematic review and meta-analysis. However, due to the small number and inconsistent quality of the underlying research, the present results should be regarded with caution [33].

Therefore, hypoxia is a biologically plausible mechanism in OSMF-associated carcinogenesis; nevertheless, HIF expression alone is still insufficient to predict the malignancy of a single lesion. To determine the clinical relevance of these indicators, more long-term research is required.

Genetic and Epigenetic Alterations

The onset and course of OSMF may be influenced by acquired molecular changes and genetic predisposition. Changes in gene expression, DNA damage, epigenetic regulation, and signaling pathways linked to fibrosis and oral carcinogenesis have all been studied. Genes involved in cell proliferation, differentiation, death, and extracellular matrix modulation may be impacted by

epigenetic processes, such as DNA methylation, histone modifications, and changed expression of non-coding RNAs [34].

Numerous molecular pathways, such as TGF-β/Smad, PI3K/AKT, NF-κB, and pathways related to the epithelial–mesenchymal transition (EMT), have been studied. Although their exact role in OSMF-associated malignant transformation is still unknown, EMT-related alterations may modify epithelial cell adhesion and behavior. Similarly, molecular changes found in tissue samples shouldn't always be regarded as reliable biomarkers for diagnosis or prognosis. Independent validation, repeatability, and proof of beneficial diagnostic performance are necessary for their therapeutic significance [35].

Integrated Model of Malignant Transformation.

A multifactorial hypothesis of OSMF-associated carcinogenesis is supported by the research currently under publication. Frequent exposure to areca nuts can cause oxidative stress and epithelial damage, as well as fibroblast activation and aberrant collagen metabolism. While persistent inflammation and molecular alterations may affect epithelial stability, progressive fibrosis can impact tissue architecture and oxygen availability. Additional changes may potentially lead to epithelial dysplasia and invasive OSCC in susceptible people [36].

It is not appropriate to view this model as a linear or inevitable succession. Not all OSMF patients go on to develop cancer, and each patient may have a different relative importance for each pathway. More research is needed to determine how exposure history, host susceptibility, tissue alterations, and other carcinogenic variables interact.

MALIGNANT TRANSFORMATION OF OSMF INTO ORAL SQUAMOUS CELL CARCINOMA

Epidemiology And Risk of Malignant Transformation

Oral submucous fibrosis (OSMF) is acknowledged as an oral possibly malignant condition linked to an elevated risk of oral squamous cell carcinoma (OSCC), building on the pathogenic processes discussed in the previous section. Numerous observational studies and systematic reviews have examined the risk of malignant transformation; however, reported estimates differ depending on the research population, follow-up period, diagnostic criteria, and methodological quality [37].

A systematic review and meta-analysis by Kujan et al. reported a pooled malignant transformation proportion of approximately 4.2% among patients with OSMF, with a 95% confidence interval of 2.7%–5.6%. The authors also reported an estimated annual transformation rate of 0.73%. However, limitations in the underlying observational studies, including the risk of bias, restrict the certainty with which these estimates can be generalized to individual patients. An umbrella review subsequently reported estimates ranging from approximately 4.2% to 6% across previous systematic reviews, highlighting the variability of the available evidence [38].

The clinical significance of long-term surveillance in patients with OSMF is highlighted by these estimations. However, it is not possible to accurately forecast when or whether a specific patient would develop OSCC based on the information now available, and pooled transformation proportions should not be regarded as an individual's lifetime risk.

Factors Associated with Malignant Transformation

Malignant transformation in oral submucous fibrosis (OSMF) is believed to result from the interaction of tissue alterations, individual susceptibility, and exposure to carcinogenic agents. Areca nut consumption is particularly important because it is the principal etiological factor associated with OSMF and can cause persistent mucosal injury through prolonged exposure to its carcinogenic constituents. Other relevant exposures, particularly tobacco smoking and smokeless tobacco use, are independently associated with an increased risk of oral cancer and should therefore be carefully documented during clinical evaluation. The frequency, duration, and type of areca nut and tobacco consumption should also be recorded to facilitate comprehensive assessment of the patient's risk profile [39].

Histopathologically confirmed epithelial dysplasia is an important finding in oral submucous fibrosis (OSMF), as it indicates abnormal epithelial maturation and is associated with an increased risk of malignant transformation. However, not all patients with OSMF develop epithelial dysplasia or oral squamous cell carcinoma (OSCC). Furthermore, the absence of dysplasia in a biopsy specimen does not eliminate the possibility of subsequent malignant transformation, as histopathological findings represent only the tissue sampled at a particular point in time. Therefore, biopsy findings should be interpreted alongside clinical features, lesion characteristics, and the adequacy and representativeness of the tissue sample. Continued clinical surveillance is important, particularly when lesions show suspicious or progressive changes [40].

Clinical changes such as persistent ulceration, focal induration, unexplained bleeding, the development of a new exophytic lesion, and persistent red, white, or mixed red-white mucosal changes warrant prompt clinical reassessment in patients with oral submucous fibrosis (OSMF). Although these features are not individually diagnostic of malignancy, they may indicate epithelial dysplasia or an underlying malignant lesion and should not be overlooked. Suspicious lesions require thorough clinical evaluation, followed by an appropriately targeted biopsy or immediate referral to a specialist for histopathological assessment, as indicated [41].

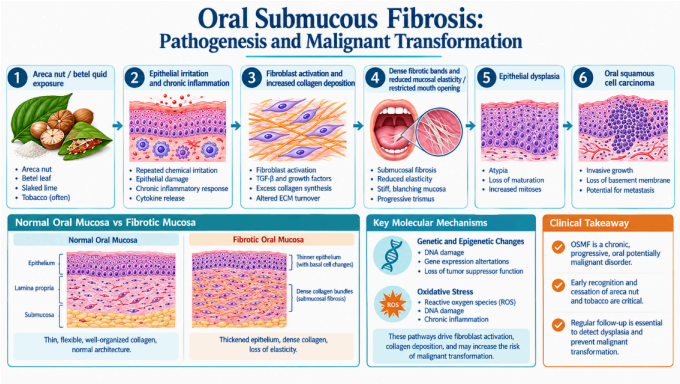

The characteristic histopathological features of oral submucous fibrosis (OSMF) include subepithelial collagen deposition and hyalinization, variable degrees of chronic inflammatory cell infiltration, altered vascularity, and epithelia

Figure 3: Schematic illustration of the pathogenesis and malignant transformation of oral submucous fibrosis (OSMF), highlighting areca nut exposure, chronic inflammation, fibroblast activation, excessive collagen deposition, submucosal fibrosis, epithelial dyspl

l atrophy. The extent and distribution of these changes may vary according to the stage of the disease and the anatomical site involved. Early lesions may exhibit oedema, inflammatory infiltration, and dilated or congested blood vessels, whereas advanced lesions typically show dense collagen bundles, reduced vascularity, and marked epithelial atrophy. Furthermore, histopathological findings may differ between patients and among different sites within the oral cavity [42].

Cellular polarity, nuclear morphology, mitotic activity, and epithelial maturation problems can all be indicators of epithelial dysplasia [43]. These histopathological alterations indicate abnormal epithelial growth and maturation and may be associated with an increased risk of malignant transformation. The defining histological feature of invasive oral squamous cell carcinoma (OSCC) is the penetration of malignant epithelial cells through the basement membrane into the underlying connective tissue, often accompanied by an infiltrative pattern of growth and stromal reaction [44].

OSMF does not always advance through a predictable series of histological phases, despite the possibility of fibrosis and epithelial changes coexisting. While some patients acquire OSCC without a history of dysplasia, others have long-term illness but do not develop malignant change. As a result, suspicious lesions should be reevaluated if their appearance or symptoms change, and clinical and histological findings must be taken into account jointly [45].

Clinical Presentation of OSCC in Patients with OSMF

When oral squamous cell carcinoma (OSCC) develops in patients with oral submucous fibrosis (OSMF), it may present clinically as a focal mucosal alteration, an area of induration, an irregular or exophytic growth, or a persistent non-healing ulcer. Early malignant lesions may remain painless; therefore, the absence of discomfort should not be considered evidence against malignancy. Furthermore, progressive restriction of mouth opening due to advanced fibrosis can make thorough examination of the oral cavity difficult, potentially delaying the detection of suspicious lesions. These factors emphasise the importance of careful and regular clinical examination in patients with OSMF [46].

A systematic clinical examination of patients with oral submucous fibrosis (OSMF) should include careful visual inspection and palpation of the entire oral cavity, including the buccal mucosa, tongue, floor of the mouth, gingiva, palate, and other accessible mucosal surfaces. Particular attention should be directed towards areas that are difficult to visualise because of restricted mouth opening associated with trismus. Any persistent or clinically suspicious mucosal lesion should undergo further evaluation, with an appropriately performed biopsy followed by histopathological examination to establish a definitive diagnosis. Where biopsy cannot be performed by the examining clinician, or specialist assessment is required, prompt referral should be arranged.

Evidence from Longitudinal Studies and Meta-Analyses

Longitudinal observational studies provide valuable evidence regarding the malignant transformation of oral submucous fibrosis (OSMF), as they allow patients to be monitored over time and document the development of oral cancer following an initial diagnosis of the condition. However, comparisons across studies remain challenging because of variations in patient selection, demographic characteristics, exposure history, duration of follow-up, and diagnostic criteria. Differences in study design and reporting quality may further contribute to the variability in reported malignant transformation rates [47].

Nine observational studies with 6,337 patients—292 of whom got oral carcinoma—were included in Kujan et al.'s meta-analysis. With an estimated yearly transformation rate of 0.73%, the pooled malignant transformation proportion was almost 4.2%. When interpreting these results, the authors stressed that methodological limitations and the possibility of bias in the included studies should be taken into account.

In a different systematic study and meta-analysis, Murthy et al. reported a pooled malignant transformation proportion of almost 6%. The variations in estimates show how methodological variance, population variables, and research selection affect aggregated results. The necessity for better longitudinal studies and more consistent reporting of malignant transformation outcomes was also emphasized in an umbrella review by Gondivkar et al.

All of these results point to OSMF as a clinically significant oral possibly malignant condition. To increase risk estimates and find trustworthy predictors of malignant transformation, future research should include established diagnostic criteria, sufficient follow-up, histological confirmation, and thorough documentation of areca nut and tobacco exposure.

Clinical Implications

Regular clinical surveillance is crucial to the therapy of OSMF because of the potential for malignant change. Patients should attend follow-up exams, seek rapid evaluation of any new or persistent mucosal changes, and receive counseling to stop using tobacco and areca nut products.

Mouth opening, mucosal texture, fibrous bands, and any new focal lesion should all be evaluated as part of the follow-up. When clinical indications indicate the possibility of epithelial dysplasia or cancer, biopsy should be taken into consideration. Clinical observations, histopathological results, exposure history, and relevant clinical guidelines should all be taken into consideration when determining the frequency of surveillance [48].

Currently, no single genetic biomarker or clinical characteristic may accurately predict malignant transition in all OSMF patients [49]. Therefore, the key components of patient care continue to be clinical vigilance, risk-factor reduction, appropriate biopsy, and ongoing follow-up.

CURRENT DIAGNOSTIC APPROACHES FOR OSMF-ASSOCIATED ORAL CANCER

The early detection of oral squamous cell carcinoma (OSCC) in patients with oral submucous fibrosis (OSMF) can be challenging because progressive fibrosis, mucosal stiffness, and restricted mouth opening may limit adequate clinical examination of the oral cavity. Although conventional oral examination remains the cornerstone of clinical assessment, no single clinical feature can reliably distinguish uncomplicated OSMF from malignant transformation. Therefore, careful evaluation of suspicious mucosal changes, supported by histopathological examination whenever indicated, is essential for the early identification of malignant lesions [50].



Figure 4: Panoramic radiograph (orthopantomogram, OPG) showing the maxillary and mandibular dentition, alveolar bone, and surrounding maxillofacial structures in a 46-year-old male patient. The radiograph provides an overview of the dentition and supporting str.

Conventional Oral Examination

The initial step in assessing patients with OSMF and spotting significant mucosal abnormalities is a traditional oral examination. It entails getting a thorough medical and dental history, recording tobacco and areca nut use, examining the oral mucosa under sufficient lighting, and palpating any questionable areas. The intraoral assessment is supplemented by extraoral examination, which includes evaluation of cervical lymph nodes when clinically necessary [51].

The buccal mucosa, retromolar area, tongue, floor of the mouth, and other areas that could be challenging to inspect due to limited mouth opening should receive special attention in patients with OSMF. The distribution of fibrous bands, mucosal blanching, tissue texture, mouth opening, and any focal ulceration, induration, growth, or persistent red or white lesion should all be noted by the clinician. When suitable and approved, serial clinical data and photos can be used to track changes over time [52].

Conventional examination is crucial for spotting worrisome lesions, but it has limited capacity to detect a lesion's histological type. Clinical examination can detect anomalies that need more research, but it cannot accurately determine if a lesion is invasive cancer or epithelial dysplasia. Therefore, appropriate diagnostic evaluation is necessary for persistent or suspected anomalies, including biopsy where necessary [53].

Biopsy and Histopathological Examination

Biopsy followed by histopathological examination remains the gold standard for confirming the diagnosis of oral squamous cell carcinoma (OSCC) and epithelial dysplasia. The decision to perform a biopsy should be guided by the clinical appearance of the lesion, its persistence or progression, and the overall level of clinical suspicion. Excisional biopsy may be appropriate for small lesions that are clinically considered benign and can be safely removed. However, incisional biopsy is generally preferred for large lesions or those suspected of malignancy, as it provides a representative tissue sample while preserving the remaining lesion for subsequent treatment planning [54].

Because lesions in OSMF may be heterogeneous, choosing the biopsy site carefully is crucial. The most clinically suspect area should be the focus of sampling, although in certain situations where abnormalities are widespread or differ between sites, more than one sample may be required. Relevant clinical data, such as the diagnosis of OSMF, lesion location, duration, appearance, and history of areca nut or tobacco exposure, should be given to the pathologist.

In addition to the connective-tissue alterations typical of OSMF, histopathological evaluation can detect epithelial atrophy, hyperplasia, dysplasia, and invasive cancer. Further clinical evaluation, additional sampling, or a referral to a specialist may be necessary if the clinical results are still suspect after an inconclusive biopsy. When clinical suspicion persists despite an initial negative biopsy result, malignancy should not be considered definitively excluded. Sampling error, inadequate tissue representation, or focal variations in the lesion may result in a false-negative diagnosis. Therefore, persistent or progressive suspicious lesions warrant repeat biopsy, additional

histopathological assessment, or specialist referral, as clinically indicated [54].

Vital Staining Techniques

Vital staining methods, especially toluidine blue, have been studied as supplements for detecting oral mucosal lesions that would need more assessment. Toluidine blue may build up in some aberrant epithelial tissues and preferentially stains specific tissue components. However, inflammation, ulceration, and other benign alterations might affect staining results, which limits the technique's specificity [55].

There is still conflicting evidence about vital staining's diagnostic accuracy. Based on extremely low-certainty data, the American Dental Association's 2026 living evidence-informed guideline advises against routinely employing vital staining as an adjunct to screen people or establish whether a biopsy is necessary. Diagnosis still heavily relies on clinical oral examination and, where necessary, biopsy.

Therefore, in individuals with suspicious lesions, vital staining should not be utilized in place of histological evaluation or to rule out malignancy [56].

Light-Based Diagnostic Techniques

The ability of light-based technologies, such as tissue autofluorescence, tissue reflectance, and chemiluminescence, to detect aberrant oral mucosa has been studied. These methods evaluate variations in tissue optical characteristics that can arise from modifications in vascularity, stromal composition, or epithelial structure.

While tissue reflectance systems measure variations in light scattering and absorption, tissue autofluorescence devices measure changes in the intrinsic fluorescence of oral tissues. Benign inflammation and other non-malignant illnesses can yield similar results, even though these techniques may aid in visualizing abnormalities. As a result, dysplasia or cancer are not always indicated by aberrant results [57].

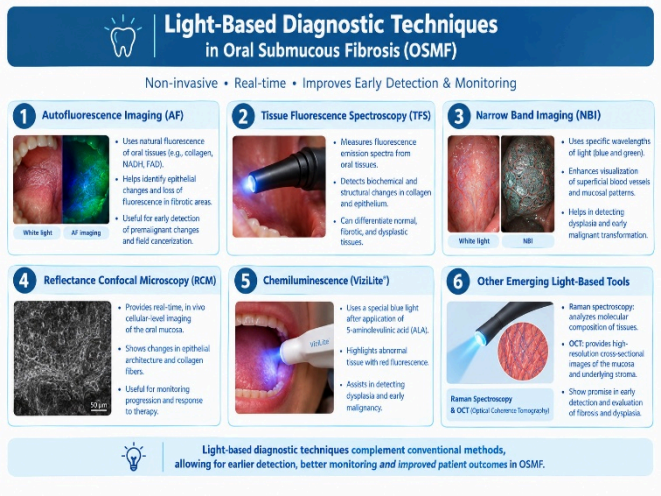

Figure 5: Overview of autofluorescence imaging, tissue fluorescence spectroscopy, narrow-band imaging, reflectance confocal microscopy, chemiluminescence, and emerging optical techniques, including Raman spectroscopy and optical coherence tomography (OCT). [22]

A 2024 systematic review of systematic reviews by Lau et al. reported insufficient evidence to support the use of several adjunctive diagnostic techniques as substitutes for conventional oral examination and surgical biopsy with histopathological assessment. The authors concluded that these techniques may have a supportive role in clinical evaluation but cannot replace established diagnostic methods. Furthermore, the 2026 American Dental Association (ADA) living guideline issued conditional recommendations against using light-based adjuncts to determine the need for biopsy or referral in patients with oral mucosal abnormalities, based on the very low certainty of the available evidence. Accordingly, conventional oral examination and histopathological evaluation remain essential for the assessment and definitive diagnosis of suspicious oral lesions [57,58].

Therefore, more research is needed to determine their potential significance in OSMF-associated cancer diagnosis, especially in prospective studies involving patients with well-characterized lesions [58].

Oral Cytology and Brush-Based Techniques

Oral cytology involves the collection and microscopic examination of cells obtained from the oral mucosa for diagnostic assessment. Brush-based cytological techniques are minimally invasive alternatives to conventional tissue sampling, allowing epithelial cells to be collected directly from the surface of a suspicious lesion. Specially designed brushes can obtain cells from different epithelial layers, which are subsequently fixed, stained, and examined for cytological abnormalities. These techniques may provide useful preliminary diagnostic information while causing less discomfort than surgical biopsy [58,59].

Nevertheless, sampling inaccuracy, insufficient cellular material, and the inability to evaluate the full tissue architecture and depth of invasion are some of the limitations of cytological examination. As a result, cytology is unable to reliably offer the information needed to differentiate all cases of invasive cancer from dysplasia.

A 2026 evidence-based recommendation advises against routinely using cytology adjuncts to evaluate if a biopsy is necessary for the majority of patients, but it permits consideration in some situations where a biopsy is neither necessary nor feasible. The preferred technique for making a conclusive diagnosis is still biopsy [57].

Molecular Biomarkers

To better identify OSMF lesions at higher risk of malignant development, molecular biomarkers are being studied. Markers linked to cell division, apoptosis, oxidative stress, inflammation, hypoxia, extracellular matrix remodeling, and genetic or epigenetic changes are among the possible choices [60].

Hypoxia-inducible factor-1 alpha (HIF-1α), p53, Ki-67, and certain microRNAs are a few examples. These compounds might shed light on cellular alterations linked to the development of cancer. However, the tissue sampled, the stage of the disease, laboratory techniques, and other biological factors can all affect how they are expressed [61].

Many biomarkers are still under investigation, despite the fact that some have demonstrated encouraging correlations with OSMF severity or malignant development [60]. Standardized testing, independent validation, and prospective evidence showing that they enhance patient outcomes or diagnostic accuracy beyond standard examination and histopathology are necessary for their routine clinical usage [52,55,60].

Salivary Biomarkers and Emerging Diagnostic Approaches

As a non-invasive source of possible biomarkers for the detection of oral cancer, saliva is being studied. Saliva has emerged as a potential non-invasive source of biomarkers for investigating molecular alterations associated with oral carcinogenesis [62]. Various salivary components, including proteins, DNA methylation patterns, RNA molecules, microRNAs, and other molecular analytes, have been studied for their possible diagnostic and prognostic significance in oral submucous fibrosis (OSMF) and oral squamous cell carcinoma (OSCC) [63]. These approaches may offer future opportunities for risk assessment and longitudinal monitoring, particularly because saliva can be collected repeatedly with minimal discomfort to the patient [64]. However, further studies are required to establish their diagnostic accuracy and determine their clinical usefulness in predicting malignant transformation in OSMF.

However, the design, sample quantity, analytical techniques, and diagnostic efficacy of salivary biomarker studies differ. A negative test cannot consistently rule out cancer, while a positive result does not always prove that cancer is present [55,64].

Since the data currently available does not support the general use of salivary adjunct tests to evaluate the need for biopsy, a 2026 live evidence-informed guideline suggests limiting them to research settings for early oral cancer diagnosis. Before these techniques may be incorporated into routine clinical practice, larger prospective investigations are needed.

Optical Coherence Tomography (OCT)

Optical coherence tomography (OCT) is a non-invasive imaging technique that uses low-coherence near-infrared light to generate high-resolution, cross-sectional images of oral tissues. It enables visualisation of tissue microarchitecture, including epithelial thickness, epithelial stratification, and changes in the underlying connective tissue. OCT has potential applications in the assessment of epithelial and stromal alterations associated with oral potentially malignant disorders (OPMDs), including changes that may be relevant to oral submucous fibrosis (OSMF). However, its ability to accurately assess the extent of subepithelial fibrosis and predict malignant transformation in OSMF requires further investigation [65].

Optical Spectroscopy

Techniques such as Raman spectroscopy and Fourier-transform infrared (FTIR) spectroscopy have been investigated for identifying biochemical and structural changes in oral tissues. Their application in routine OSMF diagnosis remains under investigation [66].

These techniques should currently be considered adjunctive rather than replacements for conventional clinical examination and histopathological assessment.

Comparative Overview of Diagnostic Approaches

Diagnostic method	Main role	Important limitation
Conventional oral examination	Identifies and documents suspicious mucosal changes	Cannot confirm histological diagnosis
Biopsy and histopathology	Confirms dysplasia or invasive carcinoma	Sampling error may occur
Vital staining	Investigated as an adjunct for lesion assessment	Limited evidence; false-positive results
Light-based techniques	Visualizes tissue optical changes	Cannot reliably distinguish benign from malignant lesions
Oral cytology	Evaluates sampled epithelial cells	Does not provide complete tissue architecture
Molecular biomarkers	Investigates biological changes associated with carcinogenesis	Most require further clinical validation
Salivary biomarkers	Non-invasive research into cancer detection	Insufficient evidence for routine clinical use

Table 1: Diagnostic Methods for the Assessment of Oral Potentially Malignant Disorders and Oral Cancer

Clinical Implications and Future Directions

Clinical examination, identification of worrisome alterations, and prompt histological evaluation should serve as the foundation for the diagnostic evaluation of OSMF-associated

oral cancer. Although there may be research potential with adjunctive technologies, the available data do not justify using them in place of traditional inspection or biopsy.

Prospective studies with clearly defined OSMF populations, standardized diagnostic procedures, and sufficient follow-up should be given top priority in future research. Risk stratification may potentially be improved by combining clinical risk variables with validated molecular or imaging biomarkers, but before such methods are routinely used, their clinical utility must be demonstrated.

Managing individuals with OSMF still requires early detection of suspicious lesions, quitting tobacco and areca nut usage, and ongoing clinical surveillance.

CURRENT MANAGEMENT AND PREVENTIVE STRATEGIES

Current Management of Oral Submucous Fibrosis

The goals of treating oral submucous fibrosis (OSMF) are to lessen symptoms, enhance mouth opening, prevent additional exposure to carcinogens, and detect malignant alterations early on. Depending on the severity of the illness, treatment options include counseling for quitting habits, nutritional support when deficiencies are found, symptomatic care, physical therapy, and, in certain advanced cases, surgery. Nevertheless, there is still insufficient data to support numerous therapy techniques, and no single treatment has been proven to provide a permanent cure for OSMF.

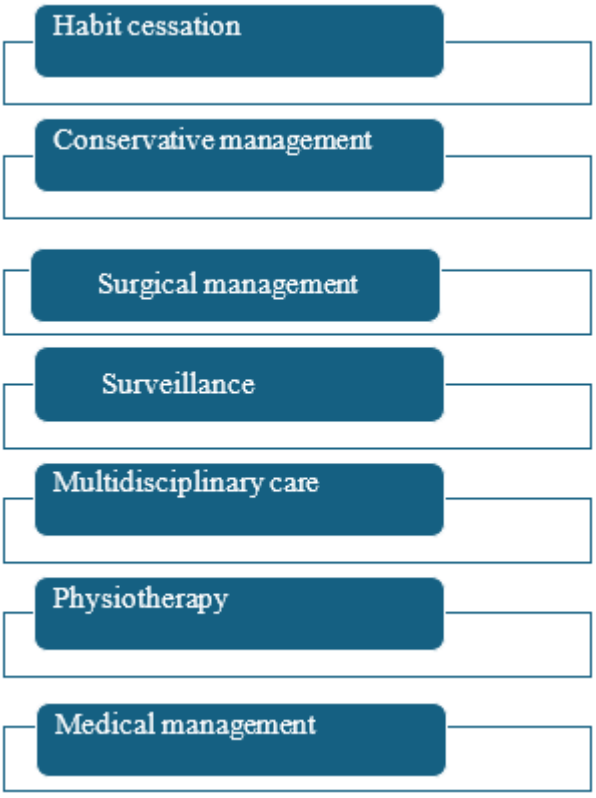

Figure 6: Overview of Management Strategies for Oral Potentially Malignant Disorders

To address functional restriction, conservative care may involve various physiotherapy techniques and supervised mouth-opening exercises. Studies have looked into the effectiveness of hyaluronidase, intralesional corticosteroids, and other medical treatments for improving mouth opening and relieving symptoms. Surgical release of fibrous bands and suitable repair, followed by rehabilitation, may be necessary in cases of advanced illness with severe trismus. The severity of the disease and the patient's clinical state should be taken into consideration while choosing a treatment plan [67].

Prevention and Cessation of Areca Nut and Tobacco Use

Tobacco use and areca nut consumption need special attention in order to prevent OSMF progression and lower the risk of oral cancer. Even when eaten without tobacco, areca nuts are known to cause cancer in humans [68]. Patients should be advised to stop using tobacco-containing products, betel quid, gutka, and areca nuts. When necessary, behavioral support and suitable cessation programs should be provided.

Public health initiatives are similarly crucial, especially in areas where areca nut products are socially acceptable and easily accessible. Exposure can be decreased by community education, school-based awareness programs, efficient enforcement of relevant laws, and transparent communication about the dangers of tobacco and areca nuts. To support significant behavioral change, prevention measures should be sustained over time and culturally acceptable.

Surveillance and Early Detection of Malignant Transformation

Patients with OSMF are still at risk of oral squamous cell carcinoma (OSCC); hence, long-term monitoring is crucial. The oral mucosa should be thoroughly examined, mouth openness should be evaluated, and any new or persistent lesions should be assessed as part of the surveillance. Prompt clinical reevaluation and biopsy are necessary when ulceration, induration, unexplained bleeding, or persistent red or white changes occur [69].

In order to confirm OSCC or epithelial dysplasia, histopathological testing is still essential. In certain situations, adjunctive diagnostic technologies could help with clinical assessment, but they shouldn't take the place of proper biopsy and histological analysis. Clinical results, histology, continued exposure to carcinogens, and pertinent clinical guidelines should all be taken into consideration when determining the frequency of follow-up.

Future Research Directions

Finding trustworthy biomarkers that can identify OSMF patients at increased risk of malignant transformation should be the main goal of future research. To enhance risk estimates and elucidate the role of clinical, histological, and molecular variables, large prospective studies employing established

diagnostic criteria, consistent follow-up, and thorough exposure histories are required [70].

The long-term efficacy of current OSMF treatments, the advantages of organized surveillance programs, and community-based strategies for lowering areca nut intake should all be assessed in future research. Better clinical results and an earlier diagnosis may be supported by increased access to oral examination and biopsy facilities, especially in high-incidence areas.

RESEARCH GAPS AND FUTURE DIRECTIONS

Even though our knowledge of oral submucous fibrosis (OSMF) has advanced, there are still significant research gaps in terms of anticipating malignant transformation and enhancing long-term patient outcomes. Direct comparisons are challenging because current research differs in terms of diagnostic criteria, follow-up time, population characteristics, and reported transformation rates. To provide more accurate estimates of oral squamous cell carcinoma (OSCC) risk in patients with OSMF, large, prospective, multicenter studies employing standardized clinical and histological criteria are required.

Finding trustworthy molecular and salivary biomarkers that can identify people at higher risk of malignant transformation should be the main goal of future research. Combining molecular data, histological alterations, and clinical findings may enhance risk assessment and provide more customized monitoring. However, before these methods can be regularly used in clinical practice, they must be validated in sizable independent population.

Further research is needed to determine the long-term safety and effectiveness of current OSMF treatments, particularly their ability to improve mouth opening, reduce symptoms, and halt the disease's progression. Standardized clinical research comparing drugs, physical therapy, and surgery could help build evidence-based treatment protocols [26].

Prevention is another important topic of research. Evaluating culturally appropriate areca nut cessation programs, community education, and public health activities may reveal effective ways to reduce exposure to recognized carcinogens. Improving oral examinations, biopsy services, and long-term follow-up for high-risk individuals is equally important.

All things considered, molecular analysis, standardized clinical trials, effective prevention, and improved surveillance should all be incorporated into future research. These programs could reduce the incidence of OSMF-related oral cancer, enhance evidence-based care, and assist in early detection of high-risk people.

DISCUSSION

Oral submucous fibrosis (OSMF) remains an important oral health concern because of its progressive nature, functional complications, and potential for malignant transformation. Although its association with areca nut consumption is well established, the development of oral squamous cell carcinoma (OSCC) appears to involve several interconnected biological processes rather than a single mechanism. The available evidence suggests that persistent epithelial injury, oxidative stress, inflammation, and changes in extracellular matrix metabolism may collectively contribute to an environment that favours carcinogenesis [12,13].

An important point is that fibrosis itself does not inevitably lead to cancer. Molecular alterations associated with areca nut exposure and changes in cellular signalling may contribute to malignant progression, but their individual roles in human disease are not yet fully understood [12,30]. This distinction is clinically relevant because patients with OSMF may have different disease courses, even when they share similar clinical features or exposure histories.

The reported risk of malignant transformation further highlights the need for continued observation. Previous systematic reviews have reported transformation estimates of approximately 4.2% to 6%; however, differences in study populations, follow-up periods, and methodological quality make direct comparisons difficult [10,11]. These figures indicate a meaningful risk at the population level, but they should not be interpreted as an accurate prediction of an individual patient's outcome. Long-term follow-up is therefore important, particularly when patients continue to use areca nut or tobacco products.

Early recognition of suspicious mucosal changes remains one of the most important aspects of clinical management. Conventional oral examination allows clinicians to document changes in mucosal appearance, texture, and mouth opening. However, visual examination alone cannot establish the presence or grade of epithelial dysplasia or confirm malignancy. Histopathological examination of an appropriately selected biopsy remains essential when a lesion is clinically suspicious [15,16]. If clinical suspicion persists despite an inconclusive initial assessment, further evaluation and appropriate referral should be considered.

Several adjunctive diagnostic methods have been investigated to improve the detection of potentially malignant changes. Vital staining, light-based techniques, oral cytology, and optical imaging may provide additional information during clinical assessment. Nevertheless, current evidence does not support their use as replacements for conventional examination and biopsy [14,15,57–59]. Similarly, molecular and salivary biomarkers are promising areas of research, but differences in study methods and the lack of sufficient clinical validation currently limit their routine application [60–64]. Their future value will depend on demonstrating that they can improve diagnostic accuracy or patient outcomes beyond established clinical and histopathological methods.

Prevention and regular surveillance should remain central to the management of OSMF. Patients need clear advice regarding complete cessation of areca nut and tobacco use, along with

appropriate support to help them maintain these changes. Long-term clinical assessment is also necessary because improvement in symptoms or mouth opening does not necessarily indicate that the risk of malignant transformation has disappeared. Persistent ulceration, induration, unexplained bleeding, or new red or white mucosal changes should prompt timely reassessment and biopsy when indicated [68,69].

Overall, the available literature shows that although understanding of OSMF-associated carcinogenesis has improved, predicting which patients will develop OSCC remains difficult. Larger prospective studies using consistent diagnostic criteria, adequate follow-up, and well-documented exposure histories are needed. Further validation of molecular and salivary biomarkers may also help identify patients who require closer monitoring [60–64,70]. Until stronger evidence becomes available, prevention, careful clinical examination, histopathological assessment of suspicious lesions, and long-term surveillance remain the most dependable approaches to reducing the impact of OSMF-associated oral cancer.

CONCLUSION

Oral squamous cell carcinoma (OSCC) and oral submucous fibrosis (OSMF), a chronic, progressive oral disorder that may be malignant, are associated with areca nut consumption. Its pathophysiology includes anomalies of the epithelium, excessive collagen deposition, chronic inflammation, and molecular changes that could result in malignant transformation. Despite advancements in our knowledge of these pathways, accurately predicting which patients may develop OSCC remains a significant clinical challenge.

Beyond treating fibrosis and limited mouth opening, OSMF has clinical consequences. Early detection, a thorough evaluation of tobacco and areca nut consumption, and counseling for total cessation of these carcinogenic items should be the top priorities for clinicians. Individualized long-term surveillance combined with baseline documentation of mouth opening and changes in the oral mucosa can assist in determining the course of the disease. When new or chronic ulceration, induration, unexplained bleeding, or suspicious red or white lesions appear, a rapid reevaluation and biopsy should be performed. Adjunctive diagnostic tools shouldn't take the place of established diagnostic methods; histopathological testing is still necessary to confirm epithelial dysplasia or cancer.

The severity of the disease, functional impairment, histological findings, and the existence of dysplasia or OSCC should all be taken into consideration when determining the course of treatment. A comprehensive evaluation encompassing oral medicine, oral and maxillofacial surgery, pathology, and oncology may be necessary for patients with suspicious or proven malignant alterations. Clinicians should also understand that improved symptoms or greater mouth openness do not always mean that malignant potential has been eliminated. Therefore, accessible referral pathways, clear patient education, and adherence to follow-up are crucial elements of comprehensive treatment.

Validating molecular and salivary biomarkers, developing standardized surveillance procedures, and assessing therapies that can consistently slow the course of the disease and lower cancer-related morbidity should be the main goals of future research. In particular, prospective multicenter studies are required to assess the long-term efficacy of current treatments and enhance risk stratification. In conclusion, incorporating prevention, early diagnosis, evidence-based treatment, and ongoing surveillance into regular dental practice may enhance clinical results and lessen the incidence of oral cancer linked to OSMF, especially in populations where areca nut consumption is common.

ACKNOWLEDGEMENTS

The authors, Harshit Kumar, Himanshu Lakerwal, Dinesh Kumar Negi and Abhishek Parmar express their sincere gratitude to the authors also acknowledge the valuable resources provided by PubMed, Scopus, IARC and other scientific literature databases, which facilitated the identification and review of relevant published research for this article. Finally, the authors extend their appreciation to the researchers and clinicians whose work has contributed to a better understanding of oral submucous fibrosis, its malignant transformation, and current approaches to oral cancer diagnosis, prevention, and management.

REFERENCES

1. World Health Organization. Global Oral Health Status Report: Towards Universal Health Coverage for Oral Health by 2030. WHO. 2022.
2. Tan Y, Wang Z, Xu M, Li B, Huang Z, Qin S, et al. Oral squamous cell carcinomas: State of the field and emerging directions. International Journal of Oral Science.
3. Gómez I, Seoane J, Varela-Centelles P, Diz P, Takkouche B. Is diagnostic delay related to advanced-stage oral cancer? A meta-analysis. European Journal of Oral Sciences. 2009;117(5):541–546.
4. Villa A, Woo SB. Oral Potentially Malignant Disorders: A Systematic Review and Meta-analysis. Oral Oncology. 2019;98:99–105.
5. More CB, Rao NR. Oral submucous fibrosis: a contemporary narrative review with a proposed inter-professional approach for an early diagnosis and clinical management. Journal of Otolaryngology - Head & Neck Surgery. 2020;49:3.
6. Tang J, Liu J, Zhou Z, Cui X, Tu H, Jia J, et al. Oral submucous fibrosis: Pathogenesis and therapeutic approaches. International Journal of Oral Science. 2025;17:8.
7. More CB, Rao NR. Oral submucous fibrosis: a contemporary narrative review with a proposed inter-professional approach for an early diagnosis and clinical management. Journal of Otolaryngology - Head & Neck Surgery. 2020;49:3.
8. Auluck A, Rosin MP, Zhang L, Sumanth KN. Oral submucous fibrosis, a clinically benign but potentially malignant disease: Report of 3 cases and review of the literature. Journal of the Canadian Dental Association. 2008;74(8):735–740.

9. More CB, Rao NR. Oral submucous fibrosis: a contemporary narrative review with a proposed inter-professional approach for an early diagnosis and clinical management. Journal of Otolaryngology - Head & Neck Surgery. 2020;49:3.
10. Kujan O, Mello FW, Warnakulasuriya S. Malignant Transformation of Oral Submucous Fibrosis: A Systematic Review and Meta-Analysis. Oral Diseases. 2021;27(8):1936–1946.
11. Gondivkar SM, Yuwanati M, Sarode SC, Gadbail AR, Gondivkar R, Mohsin SF, et al. Malignant Transformation in Oral Submucous Fibrosis: Tertiary Level Evidence: An Umbrella Review. Oral Diseases. 2024;30(4):1818–1827.
12. Gayathri K, Malathi N, Gayathri V, Adtani PN, Ranganathan K. Molecular pathways of oral submucous fibrosis and its progression to malignancy. Archives of Oral Biology. 2023;149:105644.
13. Tang J, Liu J, Zhou Z, Cui X, Tu H, Jia J, et al. Oral submucous fibrosis: Pathogenesis and therapeutic approaches. International Journal of Oral Science. 2025;17:8.
14. Lau J, Guru O, Warnakulasuriya S, Balasubramaniam R, Frydrych A, Kujan O. Adjunctive aids for the detection of oral squamous cell carcinoma and oral potentially malignant disorders: A systematic review of systematic reviews. Japanese Dental Science Review. 2024;60:53–72.
15. Walsh T, Macey R, Kerr AR, Lingen MW, Ogden GR, Warnakulasuriya S. Diagnostic tests for oral cancer and potentially malignant disorders in patients presenting with clinically evident lesions. Cochrane Database of Systematic Reviews. 2021;7(7):CD010276.
16. Lingen MW, Abt E, Agrawal N, Chaturvedi AK, Cohen E, D'Souza G, et al. Evidence-based clinical practice guideline for the evaluation of potentially malignant disorders in the oral cavity: A report of the American Dental Association. Journal of the American Dental Association. 2017;148(10):712–727.e10.
17. Gayathri K, Malathi N, Gayathri V, Adtani PN, Ranganathan K. Molecular pathways of oral submucous fibrosis and its progression to malignancy. Archives of Oral Biology. 2023;149:105644.
18. Mokal CN, Das M, Hannenhalli S, Agrawal P. Oral submucosal fibrosis: a comprehensive review on pathogenesis, diagnosis, therapeutics and computational advances. Frontiers in Cell and Developmental Biology. 2025;13.
19. Tang J, Liu J, Zhou Z, Cui X, Tu H, Jia J, et al. Oral submucous fibrosis: Pathogenesis and therapeutic approaches. International Journal of Oral Science. 2025;17:8.
20. Prabhu RV, Prabhu V, Chatra L, Shenai P, Suvarna N, Dandekeri S. Areca nut and its role in oral submucous fibrosis. J Clin Exp Dent. 2014;6(5):e569–e575.
21. International Agency for Research on Cancer. Betel-quid and areca-nut chewing. In: IARC Monographs on the Evaluation of Carcinogenic Risks to Humans. Vol. 85. Lyon, France: IARC; 2004. p. 1–334.
22. Hsieh YP, Wu KJ, Chen HM, Deng YT. Arecoline activates latent transforming growth factor β1 via mitochondrial reactive oxygen species in buccal fibroblasts: Suppression by epigallocatechin-3-gallate. J Formos Med Assoc. 2018;117(6):527–534.
23. Chang YC, Tsai CH, Lai YL, Yu CC, Chi WY, Li JJ, et al. Arecoline-induced myofibroblast transdifferentiation from human buccal mucosal fibroblasts is mediated by ZEB1. J Cell Mol Med. 2014;18(4):698–708.
24. Yang HW, Yu CC, Hsieh PL, Liao YW, Chu PM, Yu CH, Fang CY. Arecoline enhances miR-21 to promote buccal mucosal fibroblasts activation. J Formos Med Assoc. 2021;120(4):1108–1113.
25. International Agency for Research on Cancer. Arecoline. In: IARC Monographs on the Evaluation of Carcinogenic Risks to Humans. Vol. 128. Lyon: IARC; 2020.
26. Rajalalitha P, Vali S. Molecular pathogenesis of oral submucous fibrosis – a collagen metabolic disorder. J Oral Pathol Med. 2005;34(6):321–328.
27. Gupta S, Jawanda MK. Oral submucous fibrosis: An overview of a challenging entity. Indian J Dermatol Venereol Leprol. 2021;87(6):768–777.
28. Chou MY, Hsieh PL, Chao SC, Liao YW, Yu CC, Tsai CY. MiR-424/TGIF2-mediated pro-fibrogenic responses in oral submucous fibrosis. Int J Mol Sci. 2023;24(6):5811.
29. Chang YC, Yang SF, Tai KW, Chou MY, Hsieh YS. Increased tissue inhibitor of metalloproteinase-1 expression and inhibition of gelatinase A activity in buccal mucosal fibroblasts by arecoline as possible mechanisms for oral submucous fibrosis. Oral Oncol. 2002;38(2):195–200.
30. Lin F, Xiao T, Wang B, Wang L, Liu G, Wang R, Xie C, Tang Z. Mechanisms and markers of malignant transformation of oral submucous fibrosis. Heliyon. 2024;10(1):e23314.
31. Shakunthala GK, Annigeri RG, Arunkumar S. Role of oxidative stress in the pathogenesis of oral submucous fibrosis: A preliminary prospective study. Contemp Clin Dent. 2015;6(Suppl 1):S172–S174.
32. Qin X, Ning Y, Zhou L, Zhu Y. Oral submucous fibrosis: etiological mechanism, malignant transformation, therapeutic approaches and targets. Int J Mol Sci. 2023;24(5):4992.
33. Keerthika R, Chandra A, Jain T, Singh N, Agrawal R. An enigmatic pathogenetic mechanism of hypoxia inducible factor-1/2 alpha in the progression of fibrosis of oral submucous fibrosis and its malignant transformation: A systematic review and meta-analysis. Arch Oral Biol. 2024;162:105944.
34. Kundu P, Pant I, Jain R, Rao SG, Kondaiah P. Genome-wide DNA methylation changes in oral submucous fibrosis. Oral Dis. 2022;28(4):1094–1103.
35. Kavitha L, Ranganathan K, Shyam S, Fathima JHS, Umesh W, Warnakulasuriya S. Immunohistochemical biomarkers in oral submucous fibrosis: A scoping review. J Oral Pathol Med.
36. Gayathri K, Malathi N, Gayathri V, Adtani PN, Ranganathan K. Molecular pathways of oral submucous fibrosis and its progression to malignancy. Arch Oral Biol. 2023;148:105644.
37. Murthy V, Mylonas P, Carey B, Yogarajah S, Farnell D, Addison O, et al. Malignant transformation rate of oral submucous fibrosis: A systematic review and meta-analysis. J Clin Med. 2022;11(7):1793.
38. Gondivkar SM, Yuwanati M, Sarode SC, Gadbail AR, Gondivkar R, Mohsin SF, et al. Malignant transformation in oral submucous fibrosis: Tertiary level evidence: An umbrella review. Oral Dis. 2024;30(4):1818–1827.
39. Murthy V, Mylonas P, Carey B, Yogarajah S, Farnell D, Addison O, et al. Malignant transformation rate of oral submucous fibrosis: A systematic review and meta-analysis. J Clin Med. 2022;11(7):1793.
40. Muller S, Tilakaratne WM. Update from the 5th Edition of the World Health Organization Classification of Head and Neck Tumors: Tumours of the Oral Cavity and Mobile Tongue. Head Neck Pathol. 2022;16(1):54–62.

41. International Agency for Research on Cancer. A digital manual for the early diagnosis of oral neoplasia. Lyon: IARC.
42. Shih YH, Wang TH, Shieh TM, Tseng YH. Oral submucous fibrosis: A review on etiopathogenesis, diagnosis, and therapy. Int J Mol Sci. 2019;20(12):2940.
43. Warnakulasuriya S, Kujan O, Aguirre-Urizar JM, Bagan JV, González-Moles MÁ, Kerr AR, et al. Oral potentially malignant disorders: A consensus report from an international seminar on nomenclature and classification convened by the WHO Collaborating Centre for Oral Cancer. Oral Dis. 2021;27(8):1862–1880.
44. Muller S, Tilakaratne WM. Update from the 5th Edition of the World Health Organization Classification of Head and Neck Tumors: Tumours of the Oral Cavity and Mobile Tongue. Head Neck Pathol. 2022;16(1):54–62.
45. Muller S, Tilakaratne WM. Update from the 5th Edition of the World Health Organization Classification of Head and Neck Tumors: Tumours of the Oral Cavity and Mobile Tongue. Head Neck Pathol. 2022;16(1):54–62.
46. Jayasinghe RD, Siriwardena BSMS. Clinical aspects of oral cancer and potentially malignant disorders with special relevance to South Asia. Ann Maxillofac Surg. 2025;14(2):128–136.
47. Albuquerque R, et al. Malignant transformation rate of oral submucous fibrosis: A systematic review and meta-analysis. J Clin Med. 2022;11(7):1793.
48. Kujan O, Mello FW, Warnakulasuriya S. Malignant Transformation of Oral Submucous Fibrosis: A Systematic Review and Meta-Analysis. Oral Dis. 2021;27(8):1936–1946.
49. Singh AG, Roy S, Oza S, Singhavi H, Chatterjee K, Chaturvedi P. A contemporary narrative review to guide molecular epidemiology of oral submucous fibrosis. Int J Mol Epidemiol Genet. 2021;12(4):61–70.
50. Jayasinghe RD, Siriwardena BSMS. Clinical aspects of oral cancer and potentially malignant disorders with special relevance to South Asia. Ann Maxillofac Surg. 2025;14(2):128–136.
51. Ministry of Health and Family Welfare, Government of India. Operational framework: Management of common cancers. Official document.
52. More CB, Rao NR, Villa A, Jayasinghe RD, Kerr AR, Johnson NW. Oral submucous fibrosis: A contemporary narrative review with a proposed inter-professional approach for an early diagnosis and clinical management. J Otolaryngol Head Neck Surg. 2020;49:3.
53. Lingen MW, Abt E, Agrawal N, Chaturvedi AK, Cohen E, D'Souza G, et al. Evidence-based clinical practice guideline for the evaluation of potentially malignant disorders in the oral cavity: A report of the American Dental Association. J Am Dent Assoc. 2017;148(10):712–727.e10.
54. Gates JC, Edwards H, Villa A, Troka M, et al. Biopsy for suspicious oral lesions: A review from the American Head and Neck Society-Cancer Prevention Service. Head Neck. 2026;48(3):884–892.
55. Walsh T, Macey R, Kerr AR, Lingen MW, Ogden GR, Warnakulasuriya S. Diagnostic tests for oral cancer and potentially malignant disorders in patients presenting with clinically evident lesions. Cochrane Database Syst Rev.
56. Lingen MW, Abt E, Agrawal N, Chaturvedi AK, Cohen E, D'Souza G, et al. Evidence-based clinical practice guideline for the evaluation of potentially malignant disorders in the oral cavity: A report of the American Dental Association. J Am Dent Assoc. 2017;148(10):712–727.e10.
57. Bhosale AS, Martins-Pfeifer C, Verdugo-Paiva F, Urquhart O, Carrasco-Labra A, Pimentel J, et al. Living evidence-informed guideline on the early detection of oral squamous cell carcinoma and potentially malignant disorders: Light-based adjuncts to determine the need for biopsy, Version 2026 1.0. J Am Dent Assoc. 2026;157(9):968–979.
58. Lau J, Guru O, Warnakulasuriya S, Balasubramaniam R, Frydrych A, Kujan O. Adjunctive aids for the detection of oral squamous cell carcinoma and oral potentially malignant disorders: A systematic review of systematic reviews. Jpn Dent Sci Rev. 2024;60:53–72.
59. Rajsri KS, Durab SK, Varghese IA, Vigneswaran N, McDevitt JT, Kerr AR, et al. A brief review of cytology in dentistry. Br Dent J. 2024;236:329–336.
60. Lin F, Xiao T, Wang B, Wang L, Liu G, Wang R, et al. Mechanisms and markers of malignant transformation of oral submucous fibrosis. Heliyon. 2024;10(1):e23314.
61. Singh AG, Roy S, Oza S, Singhavi H, Chatterjee K, Chaturvedi P. A contemporary narrative review to guide molecular epidemiology of oral submucous fibrosis. Int J Mol Epidemiol Genet. 2021;12(4):61–70.
62. Mahdani FY, Subarnbhesaj A, Ayuningtyas NF, Surboyo MDC, Bakti RK, Radithia D, et al. Salivary profile in oral submucous fibrosis: A scoping review. Eur J Dent. 2025;19(1):24–36.
63. Efficacy of hypermethylated DNA biomarkers in saliva and oral swabs for oral cancer diagnosis: Systematic review and meta-analysis. Oral Dis. 2022;28(3):541–558.
64. Bastías D, Maturana A, Marín C, Martínez R, Niklander SE. Salivary biomarkers for oral cancer detection: An exploratory systematic review. Int J Mol Sci. 2024;25(5):2634.
65. Optical coherence tomography: Promising imaging technique for the diagnosis of oral mucosal diseases. Oral Dis. 2024;30(6):3638–3651.
66. Diagnostic accuracy of vibrational spectroscopy in the diagnosis of oral potentially malignant and malignant disorders: A systematic review and meta-analysis.
67. Jones A, Veale B, Li T, Aggarwal VR, Twigg J. Interventions for managing oral submucous fibrosis. Cochrane Database Syst Rev. 2024;2(2):CD007156.
68. International Agency for Research on Cancer. IARC handbooks of cancer prevention. Volume 19: Oral cancer prevention. Lyon: International Agency for Research on Cancer; 2023.
69. Ramani P, Hazarey VK, Ranganathan K, Chattopadhyay J, Angadi P, Tilakarathne WM, et al. Global expert consensus on oral submucous fibrosis: Standardizing care, surveillance, and prevention strategies. J Oral Maxillofac Pathol. 2026;30(1):2–13.
70. Kavitha L, Ranganathan K, Shyam S, Fathima JHS, Wadgave U, Warnakulasuriya S. Immunohistochemical biomarkers in oral submucous fibrosis: a scoping review. J Oral Pathol Med. 2022;51(7):594–602.